International Association for the Study of Pain
IASP®
Working together for pain relief

PAIN CLINICAL UPDATES

Editorial Board

Editor-in-Chief

Jane C. Ballantyne, MD, FRCA
Anesthesiology, Pain Medicine
USA

Advisory Board

Michael J. Cousins, MD, DSC
Pain Medicine, Palliative Medicine
Australia

Maria Adele Giamberardino, MD
Internal Medicine, Physiology
Italy

Robert N. Jamison, PhD
Psychology, Pain Assessment
USA

Patricia A. McGrath, PhD
Psychology, Pediatric Pain
Canada

M.R. Rajagopal, MD
Pain Medicine, Palliative Medicine
India

Maree T. Smith, PhD
Pharmacology
Australia

Claudia Sommer, MD
Neurology
Germany

Harriët M. Wittink, PhD, PT
Physical Therapy
The Netherlands

Publishing

Ivar Nelson, Publications Director

Elizabeth Endres, Associate Editor

Upcoming Issues

Metric-Based Pain Care
Contemporary Physical Therapy
Marijuana and Pain

Vol. XX, Issue 6 October 2012

Advanced Neuroimaging for the Study of Migraine Pathophysiology

Migraine is a complex neurological disorder characterized by repetitive attacks with abnormal sensory perception with head pain, sensitivity to light as well as sounds and smells, and nausea.[1] It is highly prevalent throughout the world and has a strong genetic background, although monogenetic forms are rare. At onset, the disorder is usually episodic, but it can transform into a chronic form with 15 days or more with headache per month. Mechanisms of migraine transformation are poorly understood. Although the key element of episodic migraine is the appearance of clear-cut attacks, sensory thresholds are abnormal even outside attacks,[2] and more and more literature is suggesting abnormal brain function both during and between attacks.[3] In the past two decades, functional neuroimaging has fostered our understanding of how brain function is altered in migraineurs and has provided a basis for a better understanding of attack symptoms such as pain and photophobia. A variety of PET (positron emission tomography) and MRI (magnetic resonance imaging) methods (see Table I) make it possible to study both brain structure and cerebral function. This issue of *Pain: Clinical Updates* will review the pertinent literature and summarize how neuroimaging may affect clinical migraine management in the future.

Migraine and the Brainstem

A pivotal PET study showed an increase of blood flow (a surrogate for neuronal activation) in the brainstem and several supratentorial brain areas during spontaneous migraine attacks in nine patients. After treatment with sumatriptan, the brainstem activation persisted, whereas the neocortical activations subsided.[4] The persistence of brainstem activation throughout the attack led to three suggestions: (1) Brainstem activation could be specific to migraine attacks and may explain several of the clinical aspects of migraine. (2) Acute medications such as triptans have no effect on this central activation, and thus the headache may recur when the medication wears off. (3) This brainstem area was thus considered a "migraine generator" acting as a trigger or accelerator of an acute attack.

Brainstem activation could be specific to migraine attacks and may explain several of the clinical aspects of migraine

Several newer PET studies have confirmed this observation with evidence of convergent dorsal pontine activation in both spontaneous and experimentally triggered migraine attacks.[4] The brainstem activation predominantly occurs ipsilaterally to the manifestation of the pain, which suggests that the lateralization of the pain reflects

Table I Current nonconventional brain-imaging techniques applied in migraine research				
Method	Principle	Target of Study	Typical Spatial Resolution	Availability
Activation PET ($H_2{}^{15}O$ PET)	Injection of radioactively labeled water and detection of brain distribution	Spontaneous brain activity, e.g., during attacks	~5 mm	Very limited
Ligand PET	Injection of radiolabeled receptor ligands and detection of brain distribution	Receptor distributions, e.g., ictally versus interictally	~5 mm	Very limited
Functional MRI (fMRI)	Determination of changes in blood oxygenation, a surrogate for neuronal activity	Brain activation in response to stimuli	~3 × 3 × 5 mm	Wide
Functional connectivity fMRI	Detection of synchronized slow signal fluctuations in large-scale networks	Functional brain networks in the absence of stimuli	~3 × 3 × 5 mm	Wide
DTI MRI	Determination of water diffusion in brain tissue, mainly white matter	Structural brain architecture, e.g., fiber tracking	~3 × 3 × 5 mm	Wide
VBM MRI	Segmentation of T1w MRI data and detection of changes in image intensity	Changes in cortical and deep gray matter	~1 × 1 × 1 mm	Wide
Cortical thickness MRI	Segmentation of T1w MRI data	Cortical thickness with preserved folding	~1 × 1 × 1 mm, with submillimetric segmentation accuracy	Wide
Abbreviations: DTI, diffusion tensor imaging; MRI, magnetic resonance imaging; PET, positron emission tomography; VBM, voxel-based morphometry.				

lateralized brainstem dysfunction.[5] These activations may generate the pain of migraine because their location coincides with brain areas such as the periaqueductal gray matter and locus ceruleus, which modulate nociception and cortical excitability, respectively. Observations of new onset of migraine-like headache occurring after implantation of deep brain stimulators in the brainstem (periaqueductal gray matter) argue in favor of this view,[6] and colocalized changes in brain structure have been shown in migraineurs.[7] However, more recent fMRI studies, which applied the BOLD contrast (a measure related to changes in brain oxygenation), showed that during migraine attacks this area is activated both by painful stimuli[8] (Fig. 1) and by odors (which represent nonpainful stimuli),[9] indicating that this activation is not pain specific. A French group investigated seven patients with migraine during spontaneous migraine attacks with $H_2{}^{15}O$ PET within 4 hours of onset, once again after headache relief by sumatriptan injection, and also during attack-free periods.[10] The authors reported significant activations not only in the midbrain and pons but also in the hypothalamus, which, just like the brainstem activation in the first study, persisted after headache relief with sumatriptan. Hypothalamic activation had been previously reported in the trigeminal autonomic cephalgias,[11,12] but had not previously been observed in migraine. It may explain some of the premonitory symptoms, which typically start before the pain phase of an attack, but often persist throughout the attack. The hypothalamic activation may also relate to some of the circadian and autonomic features of migraine.

With the advent of improved imaging techniques and stimulation procedures, it is possible not only to study activations of

Hypothalamic activation may explain some of the premonitory symptoms, which typically start before the pain phase of an attack, but often persist throughout the attack

the trigeminal ganglion,[13] pontine nuclei, and supratentorial areas[14] in response to trigeminal stimulation, but even to detect responses in small areas such as the trigeminal nucleus caudalis (TNC), located at the medulla-C2 level.[15] A recent study evidenced a cyclical pattern of responses to painful trigeminal stimulation in the TNC of migraineurs. Interictally, stimulus-evoked responses were attenuated in migraine patients as compared to healthy controls, but when a migraine attack was imminent, the activation pattern normalized. Interestingly, the interictal TNC response predicted the time of the next migraine attack. Given that the brainstem was not specifically activated before the attack and given the clinical progression of the migraine cycle, it is tempting to consider oscillating impulse generators in the limbic system, perhaps including the hypothalamus, which may have (indirect) modulating effects on the activation level of the trigeminal nuclei just before an attack, followed by a specific activation of the rostral parts of the pons during the actual headache attack. Either way, the spinal trigeminal nuclei are key structures with rising excitability toward a migraine attack, whereas the increased activation in the rostral pons, previously termed the "migraine generator," probably occurs on a secondary level and only during the attack.[16] In conclusion, dysfunction of the regulation of brainstem nuclei involved in antinociception and extra- and intracerebral vascular control provides a far-reaching explanation for many of the facets of migraine.[17,18] The importance of the brainstem

in the genesis of migraine is further underlined by the presence of binding sites for specific antimigraine compounds in brainstem structures.[19] The challenge now is to reveal the functional consequences of such findings, to understand their implications, and to assess their therapeutic potential.

Dysfunction of the regulation of brainstem nuclei involved in antinociception and extra- and intracerebral vascular control provides a far-reaching explanation for many of the facets of migraine

Migraine and the Cortex

Cortical activation has repetitively been reported in both PET and fMRI studies during migraine attacks. However, compared to the activation of the dorsal pons noted above, the pattern of cortical brain activity was less consistent across studies. Most often frontal, temporal, insular, and cingulate activations were reported during attacks, but with the exception of the temporal pole, these activations were not consistent across studies.[3] These cortical areas are well known to have a role in pain processing and also more generally in mediating the emotional salience of events. They are thus not specific to migraine. The temporal pole may be an exception because activation of this region has not been frequently reported in pain-imaging studies.[20] In a recent fMRI study, Moulton et al. showed increased activation of the temporal pole in response to trigeminal pain outside of attacks in migraineurs as compared to controls. During attacks, this relative hyperexcitability in the temporal pole was even greater. The authors also used functional connectivity analyses to study the network in which the activated area within the temporal pole may be embedded. Such connectivity studies are attracting more and more interest,[21] because researchers can use regular fMRI data (EPI sequences) to delineate the network structure of the brain by determining the synchrony of slow fluctuations of the fMRI BOLD signal in the brain. This can be done in the absence of any stimulus while the volunteers are at rest. Moulton et al. reported functional connectivity between the temporal pole and several other key areas in supraspinal pain

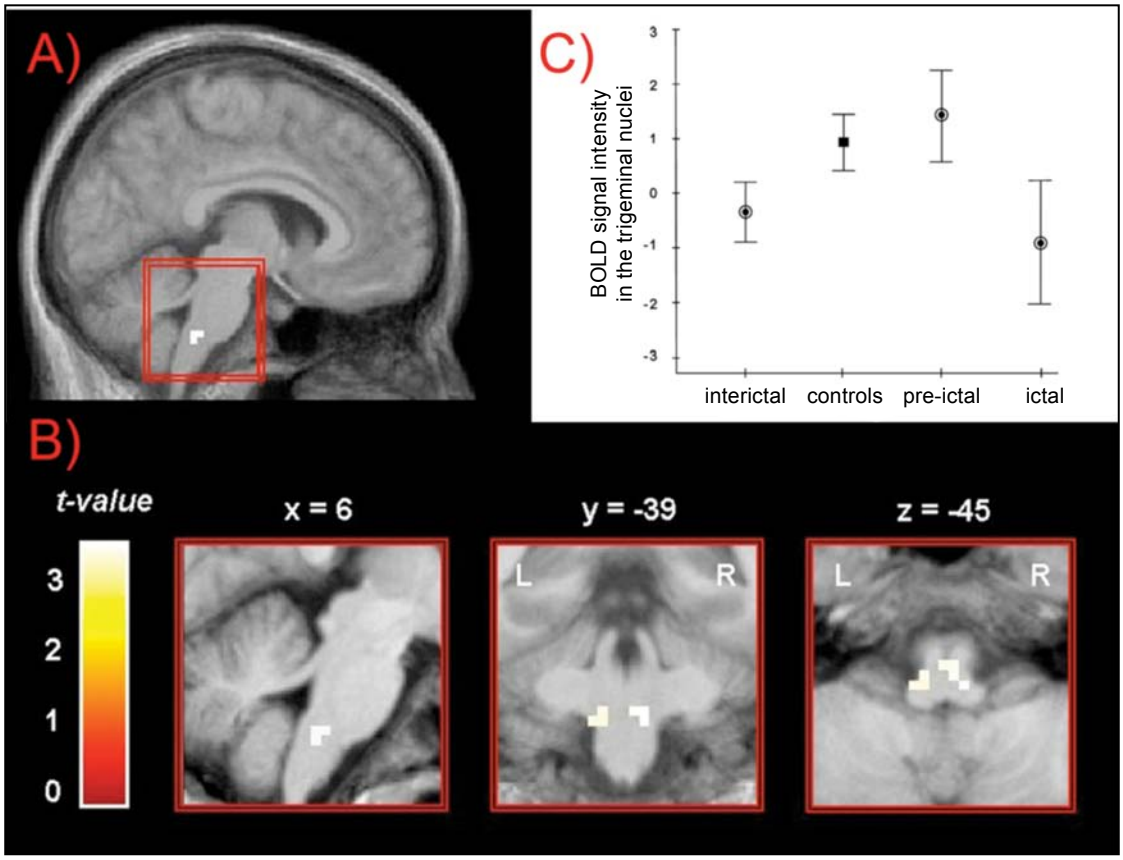

Fig. 1. (A, B) Comparison between interictal migraine patients and healthy controls. During trigeminal nociceptive stimulation of the right nostril, healthy controls ($n = 20$) showed significantly stronger bilateral activation than interictal migraineurs ($n = 20$) in a region of the brainstem corresponding to the spinal trigeminal nucleus. The activation is shown at a threshold of $P < 0.001$(uncorrected) and overlaid on the average structural image of healthy controls and interictal migraine patients. L, Left hemisphere; R, right hemisphere. (C) Relationship between blood-oxygen-level-dependent (BOLD) responses and the time to the next attack. A regression analysis demonstrated that the intensity of the BOLD response in the spinal trigeminal nuclei (independent variable) during nociceptive stimulation predicts the time to the next attack (dependent variable; day 0 on the *x*-axis, headache attack) in the group of interictal migraine patients. The diagonal line shows the regression. Reproduced with permission from Stankewitz et al.[8]

processing and showed that connectivity is indeed increased in this network in migraineurs.[22] Similarly, other authors have shown increased connectivity in pain-processing networks in migraineurs,[23] whereas functional connectivity may be reduced in pain-modulating networks.[21] Moreover, Moulton et al. used diffusion MRI-based fiber tracking for measuring structural connectivity, which indicated bilateral temporal pole connectivity with the pulvinar of the thalamus.[22] Given that this nucleus receives input from the spinothalamic and trigeminothalamic tract, the latter findings emphasize that the temporal pole may be part of a nociceptive network with abnormal functioning in migraine.

The mechanisms of migraine transformation—an increased frequency of attacks over time—are still poorly understood. A recent study shed some light on this issue by investigating migraineurs before and at the end of a week of repetitive experimental trigeminal pain stimulation.[24] The investigators showed that pain-induced responses are attenuated in antinociceptive brain areas such as the rostral anterior cingulate cortex after repetitive stimulation in migraineurs, whereas activity increases over time in non-migraine controls.[24] Hence, insufficient top-down modulation of pain may be one mechanism contributing to migraine transformation.

The mechanisms of migraine transformation—an increased frequency of attacks over time—are still poorly understood

Studies using voxel-based morphometry, a technique that can be applied to high-resolution T1-weighted MRI images in order to detect subtle abnormalities in the gray matter, have consistently shown reductions in gray matter density and volume in several cortical areas involved in pain processing, such as the anterior cingulate cortex and insula, in migraine patients as compared to controls.[25-28] Some of these studies showed that these abnormalities correlate with the duration of the disorder and/or the frequency of attacks.[25-27] Therefore, these alterations are probably consequences of repetitive attacks, and in principle, they should be reversible with proper treatment.

Recently, smaller studies have also shown abnormalities of cortical thickness in migraine, namely a thickening of the primary somatosensory cortex[29] as well as changes in visual association areas.[30] However, a larger study was not able to replicate these findings.[31] These inconsistencies may relate to differences in study populations, because the latest study on cortical thickness in migraine showed that thickening of the somatosensory cortex occurred only in subjects with higher attack frequency.[32] With the advent of sophisticated neuroimaging methods, these questions are becoming more and more relevant for our general understanding of migraine, that is, whether migraine is a progressive or potentially dangerous disease. We suggest that the findings using structural imaging techniques need to be reproduced in larger samples, possibly combining several cohorts across different scanners, to answer these questions unambiguously. What we do not need is more studies investigating even smaller cohorts with an ever-increasing arsenal of statistical methods. These questions are nevertheless highly relevant, particularly in the view of the recent discussion regarding possible interactions between cardiovascular diseases and migraine with aura.

Photophobia

Photophobia (increased sensitivity to and avoidance of light) is a prominent migraine symptom that has been addressed in several recent neuroimaging studies. Denuelle and colleagues investigated visual cortex responses to continuous luminous stimulation in migraineurs with $H_2{}^{15}O$-PET and found evidence for visual cortex hyperexcitability during attacks. Visual cortex activation in response to low luminous stimulation was stronger during the attack than after headache relief with sumatriptan. However, the activation after headache relief just after the acute attack was still stronger than during an interictal scan.[33] Hence, photophobia cannot be exclusively explained to be secondary to (severe) first trigeminal division pain. The same researchers also studied visual cortex activation in migraineurs during the interictal state as compared to healthy subjects, again with PET.[34] They found increased cortical responses in migraineurs as compared to non-migraineurs. In both groups, visual processing was modulated by concomitant painful trigeminal stimulation. These findings of Boulloche et al. in the context of Denuelle et al.'s study in acute migraine attacks[33] indicate that, while light perception and processing can be augmented by trigeminal pain in both migraine and non-migraine subjects, photophobia in migraineurs cannot be explained by the pain alone, but might be driven by modulatory brainstem circuits. Another recent study reported that interictal visual stimulation activated a larger area of the visual cortex in migraineurs as compared to controls,[35] again arguing for abnormal excitability of the visual cortex in migraine.

Photophobia in migraineurs cannot be explained by the pain alone, but might be driven by modulatory brainstem circuits

Aura

In migraine aura, the role of cortical involvement seems to be clearer than in migraine headache. About a quarter of migraine patients occasionally experience visual, somatosensory, aphasic, or motor aura, typically preceding the headache phase. In the 1940s, on the basis of observations from animal experiments, Leão suggested that cortical spreading depression (CSD) (suppression of cortical activity advancing at about 3 mm per minute over the cortex, which he observed in animals) was the electrophysiological correlate of visual aura in humans.[36] It took more than 50 years until abnormalities similar to CSD were shown electrophysiologically and in imaging studies using the ^{133}Xenon intra-arterial injection method in humans in the era before PET and fMRI were available. These imaging studies indicated spreading oligemia in migraineurs as a potential surrogate of

The thalamus is a key element of the trigeminothalamic pathway and hence would be expected to be activated during migraine attacks

CSD. Cerebral hypoperfusion during aura in the occipital cortex contralaterally to the symptoms was later confirmed by perfusion-weighted MRI.[37] Hadjikhani et al. came closest to reporting a CSD equivalent in human migraineurs when they examined a patient with migraine aura with fMRI before and during the onset of migraine aura. They observed reductions in stimulus-driven signal fluctuations in response to checkerboard stimulations, at a rate identical to CSD in the occipital cortex, concurring with the onset of visual aura in the contralateral visual hemifield.[38] The source of this wave with aura-related signal perturbations was located in the extrastriate visual cortex. These findings strongly support the view that CSD is indeed the cause of migraine aura. Interestingly, the same group later showed increased cortical thickness in migraineurs in the extrastriate cortex coinciding with the area where the CSD source was located.[30] Because of the cross-sectional study design it was not possible to determine whether such changes may be the cause or consequence of migraine aura. However, the knowledge gained by combining the results of the studies described above has profound clinical implications, because it is contraindicated to use ergotamines or triptans during the aura phase, owing to their vasoconstrictive effects. There is no problem, however, with using these substances once the aura symptoms (and hence the accompanying regional hypoperfusion of brain tissue following the CSD wave) subside, usually after 20–40 minutes.

Migraine and Subcortical Gray Matter Areas

The thalamus is a key element of the trigeminothalamic pathway and hence would be expected to be activated during migraine attacks. Indeed, a PET study investigating spontaneous migraine attacks showed thalamic activation during the attacks.[39] The activation seemed to be located in the ventromedial thalamus, probably not simply reflecting activation of the ventroposterior medial (VPM) nucleus, where most of the somatosensory trigeminothalamic relay neurons are thought to be located. However, the exact thalamic nuclei implicated in migraine are difficult to determine with current neuroimaging methods because of their small size and the limited spatial resolution of available neuroimaging methods.

Another fMRI study specifically investigated thalamic responses to non-trigeminal heat and brush stimuli in migraineurs with extracephalic allodynia.[40] The authors reported increased thalamic activation as compared to the interictal phase, suggesting thalamic involvement in the spread of allodynia from trigeminal to extratrigeminal territories as seen in some migraineurs. In this context, it is interesting that beta blockers are suggested to exert their effect on migraine frequency in the thalamus.[41]

Other subcortical gray matter areas have not traditionally been included in the framework of migraine pathophysiology. However, recent evidence indicates that the basal ganglia may have a more important role in migraine than was previously acknowledged. Maleki and colleagues showed that heat pain stimulation in migraineurs reduces basal ganglia activation while activation of the nucleus accumbens, a key structure in reward processing, is increased in high-frequency as compared to low-frequency migraineurs.[42] The consequences of such subcortical abnormalities have yet to be defined.

Migraine and White Matter

There is an ongoing debate about the significance and the possible clinical implications of white matter lesions in migraine with versus without aura. Current evidence suggests that white matter changes are relatively common in the deep white matter and subcortical U-fibers[43] in migraine with aura,[44] but uncommon in migraine without aura. Patients with a high frequency of migraine with aura and long aura duration tended to develop new lesions when followed up over almost 3 years.[45] The cause of such white matter changes in migraine with aura is unclear. Ischemic causes have been suggested, but are unproven. Migraine-related and multiple-sclerosis-related lesions appeared to be similar on MRI, but magnetization transfer ratio imaging clearly showed less tissue destruction in migraine-related lesions than in multiple sclerosis.[46] Moreover, migraine-related white matter changes seemed to be smaller and fewer than in multiple sclerosis.[43]

White matter changes are relatively common in the deep white matter and subcortical U-fibers in migraine with aura, but uncommon in migraine without aura

Nonconventional MRI studies applying diffusion tensor imaging have shown subtle white matter abnormalities in brain areas without overt lesions in migraineurs, such as reduced fractional anisotropy (FA), an indirect measure of fiber integrity, in the corpus callosum,[47] but results are not consistent across studies.[48] Rocca et al. reported selective white matter changes (reduced FA) in the optic radiation of patients with migraine with aura, whereas patients without aura had normal FA.[48] Similarly, Granziera et al. showed that fractional anisotropy is lower in migraineurs in the white matter underlying visual association areas, the superior colliculus, and the lateral geniculate ganglion,[30] but their patient population included migraineurs with and without aura, and there was no significant difference between the two migraine subgroups. Taken together, white matter abnormalities seem to be generally more common in migraine with aura, but subtle alterations, especially in the corpus callosum and visual pathways, may also occur in migraine without aura.

Conclusions and Implications for Clinical Practice

MRI techniques suitable for the study of small brain structures and the detection of subtle abnormalities are rapidly evolving. Thus, future studies on brain activation, connectivity, and structure in migraine are warranted. This research should foster our understanding of migraine pathophysiology, but it may also prove useful for diagnosis and differential diagnosis as well as treatment monitoring. New data analysis techniques such as pattern classification with machine learning algorithms may help to dissect different migraine subtypes and distinguish migraine from other primary headache disorders. Researchers are studying the usefulness of neuroimaging for determining treatment responses, and although there is still a long way to go, the initial results are promising.

Researchers are studying the usefulness of neuroimaging for determining treatment responses, and although there is still a long way to go, the initial results are promising

Neuroimaging may also guide drug development in migraine in the future. Abnormalities such as the reductions in gray matter density evidenced by voxel-based morphometry have also been shown in other chronic pain conditions such as chronic hip pain, and in this instance the changes were indeed shown to be reversible (after hip replacement).[49] This reversibility probably applies to some of the structural MRI changes observed in migraine and may represent an objective surrogate marker of disease severity, which could be targeted by preventive treatments. This marker may allow to reduce the number of subjects recruited in earlier phases of clinical drug development and hence cut costs. Other neuroimaging techniques such as resting state fMRI are also promising in this regard.

References

1. Headache Classification Committee of the International Headache Society. The International Classification of Headache Disorders, 2nd ed. Cephalalgia 2004;24 Suppl 1:9–160.
2. Drummond PD, Woodhouse A. Painful stimulation of the forehead increases photophobia in migraine sufferers. Cephalalgia 1993;13:321–4.
3. Sprenger T, Borsook D. Migraine changes the brain: neuroimaging makes its mark. Curr Opin Neurol 2012;25:252–62.
4. Weiller C, May A, Limmroth V, Jüptner M, Kaube H, Schayck RV, Coenen HH, Diener HC. Brain stem activation in spontaneous human migraine attacks. Nat Med 1995;1:658–60.
5. Afridi SK, Matharu MS, Lee L, Kaube H, Friston KJ, Frackowiak RS, Goadsby PJ. A PET study exploring the laterality of brainstem activation in migraine using glyceryl trinitrate. Brain 2005;128:932–9.
6. Raskin NH, Hosobuchi Y, Lamb S. Headache may arise from perturbation of brain. Headache 1987;27:416–20.
7. Rocca MA, Ceccarelli A, Falini A, Colombo B, Tortorella P, Bernasconi L, Comi G, Scotti G, Filippi M. Brain gray matter changes in migraine patients with T2-visible lesions: a 3-T MRI study. Stroke 2006;37:1765–70.
8. Stankewitz A, Aderjan D, Eippert F, May A. Trigeminal nociceptive transmission in migraineurs predicts migraine attacks. J Neurosci 2011;31:1937–43.
9. Stankewitz A, May A. Increased limbic and brainstem activity during migraine attacks following olfactory stimulation. Neurology 2011;77:476–82.
10. Denuelle M, Fabre N, Payoux P, Chollet F, Geraud G. Hypothalamic activation in spontaneous migraine attacks. Headache 2007;47:1418–26.
11. May A. New insights into headache: an update on functional and structural imaging findings. Nat Rev Neurol 2009;5:199–209.
12. May A, Bahra A, Buchel C, Frackowiak RS, Goadsby PJ. Hypothalamic activation in cluster headache attacks. Lancet 1998;352:275–8.
13. Borsook D, DaSilva AF, Ploghaus A, Becerra L. Specific and somatotopic functional magnetic resonance imaging activation in the trigeminal ganglion by brush and noxious heat. J Neurosci 2003;23:7897–903.
14. Sprenger T, Goadsby PJ. What has functional neuroimaging done for primary headache … and for the clinical neurologist? J Clin Neurosci 2010;17:547–53.
15. Stankewitz A, Voit HL, Bingel U, Peschke C, May A. A new trigemino-nociceptive stimulation model for event-related fMRI. Cephalalgia 2010;30:475–85.
16. Stankewitz A, Aderjan D, Eippert F, May A. Trigeminal nociceptive transmission in migraineurs predicts migraine attacks. J Neurosci 2011;31:1937–43.
17. Lance JW, Lambert GA, Goadsby PJ, Duckworth JW. Brainstem influences on cephalic circulation: experimental data from cat and monkey of relevance to the mechanism of migraine. Headache 1983;23:258–65.
18. Goadsby PJ, Zagami AS, Lambert GA. Neural processing of craniovascular pain: a synthesis of the central structures involved in migraine. Headache 1991;31:365–71.
19. Goadsby PJ, Gundlach AL. Localization of ^{3}H-dihydroergotamine-binding sites in the cat central nervous system: relevance to migraine. Ann Neurol 1991;29:91–4.
20. Peyron R, Laurent B, Garcia-Larrea L. Functional imaging of brain responses to pain. A review and meta-analysis. Neurophysiol Clin 2000;30:263–88.
21. Mainero C, Boshyan J, Hadjikhani N. Altered functional magnetic resonance imaging resting-state connectivity in periaqueductal gray networks in migraine. Ann Neurol 2011;70:838–45.
22. Moulton EA, Becerra L, Maleki N, Pendse G, Tully S, Hargreaves R, Burstein R, Borsook D. Painful heat reveals hyperexcitability of the temporal pole in interictal and ictal migraine states. Cereb Cortex 2011;21:435–48.
23. Jin C, Yuan K, Zhao L, Zhao L, Yu D, von Deneen KM, Zhang M, Qin W, Sun W, Tian J. Structural and functional abnormalities in migraine patients without aura. NMR Biomed 2012; Jun 7 [Epub ahead of print].
24. Aderjan D, Stankewitz A, May A. Neuronal mechanisms during repetitive trigemino-nociceptive stimulation in migraine patients. Pain 2010;151:97–103.
25. Kim JH, Suh SI, Seol HY, Oh K, Seo WK, Yu SW, Park KW, Koh SB. Regional grey matter changes in patients with migraine: a voxel-based morphometry study. Cephalalgia 2008;28:598–604.
26. Schmitz N, Admiraal-Behloul F, Arkink EB, Kruit MC, Schoonman GG, Ferrari MD, van Buchem MA. Attack frequency and disease duration as indicators for brain damage in migraine. Headache 2008;48:1044–55.
27. Valfre W, Rainero I, Bergui M, Pinessi L. Voxel-based morphometry reveals gray matter abnormalities in migraine. Headache 2008;48:109–17.
28. Schmidt-Wilcke T, Ganssbauer S, Neuner T, Bogdahn U, May A. Subtle grey matter changes between migraine patients and healthy controls. Cephalalgia 2008;28:1–4.
29. DaSilva AF, Granziera C, Snyder J, Hadjikhani N. Thickening in the somatosensory cortex of patients with migraine. Neurology 2007;69:1990–5.
30. Granziera C, DaSilva AF, Snyder J, Tuch DS, Hadjikhani N. Anatomical alterations of the visual motion processing network in migraine with and without aura. PLoS Med 2006;3:e402.
31. Datta R, Detre JA, Aguirre GK, Cucchiara B. Absence of changes in cortical thickness in patients with migraine. Cephalalgia 2011;31:1452–8.
32. Maleki N, Becerra L, Brawn J, Bigal M, Burstein R, Borsook D. Concurrent functional and structural cortical alterations in migraine. Cephalalgia 2012;32:607–20.
33. Denuelle M, Boulloche N, Payoux P, Fabre N, Trotter Y, Geraud G. A PET study of photophobia during spontaneous migraine attacks. Neurology 2011;76:213–8.
34. Boulloche N, Denuelle M, Payoux P, Fabre N, Trotter Y, Géraud G. Photophobia in migraine: an interictal PET study of cortical hyperexcitability and its modulation by pain. J Neurol Neurosurg Psychiatry 2010;81:978–84.
35. Martin H, del Rio MS, de Silanes CL, Alvarez-Linera J, Hernandez JA, Pareja JA. Photoreactivity of the occipital cortex measured by functional magnetic resonance imaging-blood oxygenation level dependent in migraine patients and healthy volunteers: pathophysiological implications. Headache 2011;51:1520–8.
36. Leão AAP. Spreading depression of activity in the cerebral cortex. J Neurophysiol 1944;7:359–90.
37. Sanchez del Rio M, Bakker D, Wu O, Agosti R, Mitsikostas DD, Ostergaard L, Wells WA, Rosen BR, Sorensen G, Moskowitz MA, Cutrer FM. Perfusion weighted imaging during migraine: spontaneous visual aura and headache. Cephalalgia 1999;19:701–7.

38. Hadjikhani N, Sanchez Del Rio M, Wu O, Schwartz D, Bakker D, Fischl B, Kwong KK, Cutrer FM, Rosen BR, Tootell RB, Sorensen AG, Moskowitz MA. Mechanisms of migraine aura revealed by functional MRI in human visual cortex. Proc Natl Acad Sci USA 2001;98:4687–92.

39. Afridi SK, Giffin NJ, Kaube H, Friston KJ, Ward NS, Frackowiak RS, Goadsby PJ. A positron emission tomographic study in spontaneous migraine. Arch Neurol 2005;62:1270–5.

40. Burstein R, Jakubowski M, Garcia-Nicas E, Burstein R, Jakubowski M, Garcia-Nicas E. Thalamic sensitization transforms localized pain into widespread allodynia. Ann Neurol 2010;68:81–91.

41. Shields KG, Goadsby PJ. Propranolol modulates trigeminovascular responses in thalamic ventroposteromedial nucleus: a role in migraine? Brain 2005;128:86–97.

42. Maleki N, Becerra L, Nutile L, Pendse G, Brawn J, Bigal M, Burstein R, Borsook D. Migraine attacks the basal ganglia. Mol Pain 2011;7:71.

43. Kamson DO, Illes Z, Aradi M, Orsi G, Perlaki G, Leél-Őssy E, Erdélyi-Botor S, Pótó L, Trauninger A, Pfund Z. Volumetric comparisons of supratentorial white matter hyperintensities on FLAIR MRI in patients with migraine and multiple sclerosis. J Clin Neurosci 2012;19:696–701.

44. Kurth T, Mohamed S, Maillard P, Zhu YC, Chabriat H, Mazoyer B, Bousser MG, Dufouil C, Tzourio C. Headache, migraine, and structural brain lesions and function: population-based Epidemiology of Vascular Ageing-MRI study. BMJ 2011;342:c7357.

45. Dinia L, Bonzano L, Albano B, Finocchi C, Del Sette M, Saitta L, Castellan L, Gandolfo C, Roccatagliata L. White matter lesions progression in migraine with aura: a clinical and MRI longitudinal study. J Neuroimaging 2012; Jan 23 [Epub ahead of print].

46. Rocca MA, Colombo B, Pratesi A, Comi G, Filippi M. A magnetization transfer imaging study of the brain in patients with migraine. Neurology 2000;54:507–9.

47. Li XL, Fang YN, Gao QC, Lin EJ, Hu SH, Ren L, Ding MH, Luo BN. A diffusion tensor magnetic resonance imaging study of corpus callosum from adult patients with migraine complicated with depressive/anxious disorder. Headache 2011;51:237–45.

48. Rocca MA, Pagani E, Colombo B, Tortorella P, Falini A, Comi G, Filippi M. Selective diffusion changes of the visual pathways in patients with migraine: a 3-T tractography study. Cephalalgia 2008;28:1061–8.

49. Rodriguez-Raecke R, Niemeier A, Ihle K, Ruether W, May A. Brain gray matter decrease in chronic pain is the consequence and not the cause of pain. J Neurosci 2009;29:13746–50.

Till Sprenger, MD
Departments of Neurology and Radiology
University Hospital Basel, Basel, Switzerland
Email: sprengert@uhbs.ch

Arne May, MD
Department of Systems Neuroscience, University of Hamburg
Hamburg, Germany
Email: a.may@uke.uni-hamburg.de

INFORMATION **YOU CAN COUNT ON**

Pain Comorbidities: Understanding and Treating the Complex Patient
edited by Maria Adele Giamberardino and Troels Staehelin Jensen
ISBN: 978-0-931092-92-3, paper
Price: **US$85.00** (IASP Members: US$70.00)

The Phenomenon of Pain
by Serge Marchand
ISBN 978-0-931092-91-6, paper
Price: **US$70.00** (IASP Members: $55.00)

Pain-Related Fear: Exposure-Based Treatment for Chronic Pain
by Johan Vlaeyen, Stephen Morley, Steven Linton, Katja Boersma, and Jeroen de Jong
ISBN 978-0-931092-87-9, paper
Price: **US$75.00** (IASP Members: US$60)

Pain 2012: Refresher Courses, 14th World Congress on Pain
edited by Irene Tracey
ISBN 978-0-931092-93-0, paper
Price: **US$40.00**

To get your copy, go to the IASP Bookstore on the IASP website at **www.iasp-pain.org/books**. See the website for more information, or contact the International Association for the Study of Pain at books@iasp-pain.org or call +1.206.283.0311

IASP Press®

Timely topics in pain research and treatment have been selected for publication, but the information provided and opinions expressed have not involved any verification of the findings, conclusions, and opinions by IASP. Thus, opinions expressed in *Pain: Clinical Updates* do not necessarily reflect those of IASP or of the Officers or Councilors. No responsibility is assumed by IASP for any injury and/or damage to persons or property as a matter of product liability, negligence, or from any use of any methods, products, instruction, or ideas contained in the material herein. Because of the rapid advances in the medical sciences, the publisher recommends independent verification of diagnoses and drug dosages.

For permission to reprint or translate this article, contact:

International Association for the Study of Pain • 111 Queen Anne Avenue North, Suite 501, Seattle, WA 98109-4955 USA
Tel: +1-206-283-0311 • Fax: +1-206-283-9403 • Email: iaspdesk@iasp-pain.org • www.iasp-pain.org

Copyright © 2012. All rights reserved. ISSN 1083-0707.

Printed in the U.S.A.