International Association for the Study of Pain
IASP
Working together for pain relief

Guide to Pain Management in Low-Resource Settings

Chapter 11
Physical Examination: Neurology

Paul Kioy and Andreas Kopf

Why do a neurological examination?

The main objective in a neurological examination for a patient with pain is to identify the abnormality in the nervous system that may be related to the pain experience and separate central nervous from peripheral nervous lesions. It is also important not only to establish a clinical diagnosis, but also to follow this up with anatomical, pathophysiological, etiological, and possibly pathological diagnoses, if possible. Pain is the most common reason that patients seek medical consultations, and it should be remembered that the pain may not be neurological. Indeed, in origin it often is not. In a general overview, a quick evaluation of the mental state and psychological makeup of the patient must be included as part of the neurological examination as these factors may have a significant impact on pain behavior.

In the history, the presenting symptoms are evaluated in the usual manner, which we exemplify here using one of the most common symptoms in pain patients—headaches. Headaches are important as they are a very common type of pain and one that alerts patients to a potential neurological problem, although fortunately the cause is rarely neurological. Headache still calls for a thorough neurological examination, however, as missing those uncommon neurological headaches (raised intracranial pressure, meningitis, tumors, etc.) may have catastrophic consequences.

Find out the type of headache, its character, anatomical site, severity, frequency, and duration; the nature of onset, timing and periodicity; precipitating factors (straining, coughing, posture, sex, etc.); relieving factors; and associations (visual, auditory, tactile, and dysautonomic associations etc.). Other symptoms can largely be evaluated along the same lines with variations as necessary, since not all aspects apply to all symptoms. A history of common neurological symptoms such as loss or impairment of consciousness, visual disturbances, speech and language disturbances, sensory disturbances, and motor disturbances (including sphincters) should be obtained along the same lines where possible. Further details regarding individual symptoms can be added as appropriate during direct questioning to establish potential etiological factors, including exposure to drugs (alcohol included), environmental toxins, past injuries, and systemic illnesses.

In conclusion, at least basic neurological examinations are indicated in every patient to detect somatic etiologies of pain, mainly lesions of the cerebrum, spinal cord, and peripheral nerves, including myopathies. Although in pain management the psychological factors and symptomatic treatment options are emphasized, it is crucial for the adequate understanding of the patient's pain to take a thorough history and perform a thorough physical examination. It would be harmful to our patients to overlook pain etiologies that could be treated causatively! Therefore,

Guide to Pain Management in Low-Resource Settings, edited by Andreas Kopf and Nilesh B. Patel. IASP, Seattle, © 2010. All rights reserved. This material may be used for educational and training purposes with proper citation of the source. Not for sale or commercial use. No responsibility is assumed by IASP for any injury and/or damage to persons or property as a matter of product liability, negligence, or from any use of any methods, products, instruction, or ideas contained in the material herein. Because of the rapid advances in the medical sciences, the publisher recommends that there should be independent verification of diagnoses and drug dosages. The mention of specific pharmaceutical products and any medical procedure does not imply endorsement or recommendation by the editors, authors, or IASP in favor of other medical products or procedures that are not covered in the text.

an basic neurological examination is inevitable for everybody dealing with pain patients (together with an orthopedic and psychosocial evaluation).

What is a systematic diagnostic procedure in a neurological examination?

The examiner has to use a certain systematic approach when examining the patient. Starting with the *symptoms* presented by the patient, it is advisable to continue trying to identify a *syndrome,* which includes all symptoms. A *topical diagnosis* may then be made (which is the "level" of neurological dysfunction), which should lead to the final *etiological diagnosis*. Paraclinical testings, such as electrophysiology and imaging techniques, help by confirming or ruling out a certain etiological diagnosis. However, the availability of such technical examinations is not a prerequisite to make a diagnosis in many cases. Therefore, in environments without the possibility for further testing, careful and thorough history taking and physical examination will be able to collect relevant and most often sufficient findings to make a diagnosis, helping the clinician to understand and possibly treat neurological diseases causing pain.

How do I prepare the patient for the examination?

In the usual clinical manner, establish a rapport with the patient and explain the nature and purpose of the examination to reassure him or her. Endeavour to gain the patient's confidence and trust in order to achieve the level of cooperation that is essential for the interpretation of findings. The patient should be comfortable on the examination couch and adequately but decently exposed.

How can I draw conclusions from the neurological examination?

To be able to draw conclusions from the neurological examination, it is advisable to follow a certain stepwise approach to avoid imperfection. However, following a stepwise approach does not mean being overly schematic!

It is important to explain the examination to the patient before starting because the patient's cooperation and alertness are necessary to ascertain the neurological status. If cooperation is impaired, it should be noted in the progress notes (e.g., "unexpected/inadequate finding"). Thus, objective findings such as muscle atrophy have greater value, since they may not be voluntary influenced!

Every examiner will experience at times "inadequate" or "unexpected" results from the examination. To diagnose a "psychogenic" etiology, however, thorough experience is needed. The patient should never be confronted with the suspicion of aggravation or simulation, so as to avoid an irreversible loss of mutual trust, but the suspicion should be integrated into the whole picture of the patient evaluation.

What technical support do I need for the physical neurological examination?

Everything necessary for an orientating neurological examination should be easily available. A small collection of instruments should be at hand. With a patellar hammer, a sharp instrument (e.g., a wooden stick or sterile cannulas), a soft brush or a piece of cotton wool, a wooden tongue depressor, a small flashlight, a tuning fork (128 Hz), spatulas, and a pair of glass test tubes it should be possible to detect relevant motor, coordination, trophic, and vegetative dysfunctions of the nervous system. If available, an ophthalmoscope would complete the test battery. Remember that in a very busy clinic, one may not be able to do a thorough examination for all patients. But with experience, one develops a quick and efficient personal examination protocol.

What is the stepwise approach to performing a neurological examination?

The physician normally begins the examination of any patient with an examination of the appearance of the subject in general, his/her skin and mucous membranes, followed by palpation for lumps, lymph nodes, pulses, and any superficial points of tenderness. An evaluation of vital functions should normally be done at this time, including blood pressure, pulse, respiration, and temperature. Care should of course be exercised during palpation to avoid the obvious points of severe pain and tenderness this early in the examination so as to retain the patient's cooperation.

The examiner develops a quick plan of the sequence of steps in the examination, which should be followed, because otherwise important aspects of the examination may be missed. A checklist of activities is often useful for the non-neurologist who is not yet experienced. For many, it is easy to follow the examination in a rostral caudal direction, but one may find other methods equally effective. As a bare minimum, the areas listed below must be assessed in an adult patient.

What items do I look for in the neurological examination?

- Higher functions and general examination: (look for level of consciousness, maybe use the Mini-Mental State Examination [MMSE] to test cognitive function, and check vital functions)
- Examination of the head and neck: (look for meningeal irritation, such as neck stiffness or a positive Kernig's test, check neck muscle function and neck movement)
- Examination of the cranial nerves
- Examination of the motor and musculoskeletal system (look for deformities, bulk, muscle tone, and bilateral strength)
- Examination of the sensory system (distinguish radicular and nonradicular deficits or pain radiation; check deep tendon reflexes and the "primitive" reflexes)
- Cerebellar functions (test coordination with rapid alternating hand movements, finger-nose and heel to shin test, tandem walk, one-leg stance, and Romberg test)
- For special diagnostic questions only, certain "technical" testing could be useful (laboratory tests, blood tests, cerebrospinal fluid, electrophysiology, electroencephalography, electroneuromyography, testing of autonomic functions, and imaging)

How do I evaluate "higher functions"?

The patient's degree of consciousness should be evaluated and established as this is probably the most important point in the evaluation of a patient neurologically. Most patients who will be reviewed outside the emergency department presenting with pain will not be in a coma, and an elaborate description of how to evaluate a patient in a coma may not be necessary. Nevertheless, a general familiarization with a coma scale (such as the famous Glasgow Coma Scale) may be useful.

Establish that the patient is fully conscious, able to understand and follow instructions, and fully oriented in time, space, and person. The patient's mood and emotional state (level of anxiety, depression, apathy, disinterest, posturing, and behavior) should be assessed. If any impairment is noted, a full description should be recorded as precisely as possible.

Cognitive skills can quickly assessed using simple observations during history taking and can then be supplemented by direct examination of specific skills. Assessment of language pattern and fluency can easily pick up those patients with motor dysphasia, while ability to follow instruction in the course of general examination may raise the suspicion of receptive dysphasia.

The MMSE examination of Folstein et al (Mini-Mental State Examination) is a quick formal test consisting of some 30 items which can quickly be carried out in less than 10 minutes, should suspicion of a cognitive deficit be raised. With this tool, orientation, memory and recall, abstraction, comprehension, reading, drawing, and writing ability can be assessed. Where dysphasia is marked, testing other elements of cognition is difficult, if not impossible.

How do I examine the head and neck?

Observe and palpate for deformities and tenderness in the scalp and over the muscles—especially the temporalis muscles. Tenderness over the insertion of the paraspinal and mastoids on the skull may be elicited in patients with neck muscle spasms, while occasional tenderness at the vertex may be elicited in patients with tension and depression headaches.

Check for meningeal irritation by flexing the neck and observing for stiffness and pain along the spine, and follow this with the Kernig's test. Brudzinski's sign is rarely observed in adults. Palpation for the carotid pulse will establish the presence and symmetry of the pulsations. Superficial and deep palpation of the neck muscles may elicit spasticity and tenderness and should then be followed by an assessment of neck movements in all directions, which may be restricted by pain, spasms, and/or osteoarthritis of the spine. Lhermitte's sign may occasionally be elicited in patients with multiple sclerosis and spinal canal stenosis, among other pathologies.

What does examination of the cranial nerves tell us?

The first cranial nerve is commonly examined using aromatic non-irritant or pungent materials, such as soap, which is easily available. Each nostril should be examined separately with the other blocked, and the patient is asked to determine the smell by sniffing. Abnormalities of smell are more commonly from local pathologies in the realm of otorhinolaryngology, but they can occur with base of skull and anterior fossa pathologies such as fractures and tumors.

Examination of the second cranial nerve is the most involved, but it affords the best source of information about intracranial pathology. The optic pathways traverse the whole of the brain from the frontal to the occipital pole, with the optic radiation opening out to traverse the parietal as well as the temporal lobes. Assess visual acuity roughly using a newspaper, which conveniently has type of different sizes. More accurate visual acuity measurements can be done using hand-held Snellen charts (i.e., eye charts).

Visual fields can be examined using the confrontation method in all four quadrants separately for each eye. The method compares the visual fields of the patient with that of the examiner using a colored object—usually a pin head advanced from the periphery of each quadrant. More accurate assessment can be carried out using perimetry or tangent screens.

Examination of the optic fundus may reveal invaluable information regarding raised intracranial pressure and the state of the arteries. All patients with headaches should have a funduscopy done. The state of the arteries, silver-wiring, venous pulsations, disc color and margins should be examined and noted together with hemorrhages and exudates if present.

The examination of the papillary reactions and eye movements yields further information on the second, the third, the fourth, and the sixth cranial nerves. Pupil size, shape, and reaction should be checked using a bright light for direct, consensual, and accommodation reactions and noting the symmetry and promptness of the responses. Check for ptosis (eyelid droop), and note whether it is partial or complete. Eye movements should be tested in all directions and include tests of conjugation. The presence of nystagmus should be noted and described, remembering that nystagmus at extremes of lateral gaze may be normal. Abnormalities of nystagmus reflect abnormalities in the vestibular (8th nerve) system and occasionally cerebellar lesions, although mentioned here with the eye motor nerves.

The fifth nerve is examined by assessing sensation in the face and part of the scalp in front of the ear, together with motor activity of muscles of mastication (jaw clenching and opening against resistance). Fast (touch) and slow (pinprick) sensations are handled separately as they follow different pathways and may be impaired differentially. The corneal reflex has its afferent arm in the ophthalmic division of the trigeminal nerve and would normally be included as part of its assessment.

The seventh nerve is examined by observing for facial symmetry at rest and when the patient attempts to wrinkle the forehead (lift the eyebrows), close the eyes, show the teeth, or blow out the cheeks. Taste, which is also a function of the seventh nerve, is rarely tested routinely, but it can be tested in the anterior two-thirds of the tongue using sugar or salt on the protruded tongue.

The eighth nerve function may crudely be tested using a ticking watch or by rubbing the fingers near the ear. If a hearing deficit is suspected, ensure the patency of the external auditory meatus and then carry out more elaborate tests such as Weber's test or Rinne's test to distinguish conduction from nerve deafness, or refer the patient for more sophisticated audiometry.

The ninth, 10th, and 12th nerves are examined together. One should note the presence of dysphonia, palatal movement symmetry (when the patient says *aaah*), the gag reflex, and tongue movement symmetry. Pharyngeal sensation may be tested using a wooden probe tipped with cotton wool, testing each side separately, normally as part of the gag reflex.

The 11th nerve or the spinal accessory nerve is normally examined with the rest of the motor system. The movement of shrugging the shoulders and turning the neck against resistance applied to the side of the jaw will give an indication of any weakness in the trapezius or the sternocleidomastoid muscles, respectively.

How do I examine the motor and musculoskeletal system?

General observation for muscle wasting or hypertrophy, deformities, posturing, and presence of involuntary movements (fasciculations, tremors, chorea, or athetosis) should be done. When necessary, changes

in muscle mass can further be evaluated by palpating as the muscle contracts and/or by measuring the girth of the limbs. Localized atrophy may be due to disuse because of chronic pain and should be kept in mind as a non-neurological cause of changes in muscle mass. Ensure the patient is calm and comfortable before testing tone and limb mobility. Decreased tone is usually a feature of lower motor neuron pathology, whereas increased tone (spasticity, rigidity) is a feature of upper motor neuron pathology. Limb mobility at joints should be tested in all directions allowed by the joint and any restrictions noted. One should be aware that there may be some modifications of tone and limb mobility by pain.

Muscle power is then tested in muscle groups around the joints and in the axial musculature. A good knowledge of segmental and peripheral nerve innervation of the various muscles or muscle groups is essential in evaluating the etiopathology of any weakness. If nerve-related weakness is noted, then it is imperative that it be graded according to an established scaling system such as the Medical Research Council (MRC) scale. Also, establish whether it is upper motor neuron or lower motor neuron and whether it is segmental, diffuse, distal, or peripheral in distribution. Myopathic weakness does not respect peripheral nerve or segmental demarcations and is usually more marked proximally. Neuropathic weakness needs to be delineated and assessed for the anatomical site of the pathology (spinal cord, roots, specific peripheral nerve, or diffuse neuropathy). Subtle weakness in the lower limbs may occasionally be picked up by requesting patients to rise from a squatting position, walk on their tiptoes or on their heels, while in the upper limbs one may look for pronator drift.

Other tests may be done to elicit specific deficiencies such as the straight leg raise to identify lumbar disk protrusion or the femoral stretch if higher disk pathology is suspected. There are numerous maneuvers in clinical practice aimed at eliciting specific joint or structure pathology, and these can be obtained from books on neurology and orthopedic surgery if they are needed.

How do I examine the sensory system?

The sensory system is examined guided by function and anatomy. There are two types of sensations physiologically:

Fast (posterior column, lemniscal, or discriminatory) sensations that include light touch (tested with a wisp of cotton wool), joint position sense, two point discrimination, and vibration.

Slow (spinal thalamic) sensations that traditionally are represented by pain (pinprick) and temperature sensations.

The patient is normally requested to close his/her eyes during the tests. The stimulus is applied on one side initially and then on two sides simultaneously in corresponding parts of the body. The latter tests for sensory extinction where the patient may fail to register stimulation of one side (the left usually) in lesions of the nondominant hemisphere. If any abnormalities are detected, attempts should then follow to accurately map the area of the deficit and establish the anatomical site of the lesion or the structure involved.

Pain and temperature tests yield information on the same systems, and therefore it may not be necessary to test for both in the routine patient without neuropathic pain. However, a positive increase or pathological increase in sensation (like *dysesthesia*) that may have partly been picked up during history taking will need to be elucidated further. Regions of *hyperesthesia* and *allodynia* need to be mapped out accurately, noting that skin hypersensitivity to various stimuli (touch, cold, and warmth) may be different and therefore should be tested separately.

Light touch, joint position, and vibration should be tested even though they are physiologically related in that they are all fast sensations, because they may be affected differentially in certain clinical situations.

Higher sensory functions such as two point discrimination, graphesthesia (recognition of numbers or letters drawn on the skin), and stereognosis (ability to recognize familiar objects placed in the hand) are not normally part of a routine neurological examination but can be performed where a cerebral lesion is suspected.

What does examination of the reflexes tell us?

The deep tendon reflexes are normally tested after the examination of the sensory systems. The jaw jerk, the supinator, the biceps, the triceps jerks in the upper limbs and the knee and the ankle jerks in the lower limbs are routinely tested. Others like finger flexion and adductor reflexes in the upper and lower limbs respectively are not routine. Their responses are usually graded in a simple

five point system from 0 to 4: 0 = absent, 1 = decreased, 2 = normal, 3 = increased, and 4 = increased with *clonus.* Of particular interest is the symmetry of responses and the least force necessary to elicit the responses which may be a more sensitive measure than the grading system above. Comparison between the upper limbs and the lower limbs may yield some information regarding spinal cord lesions. Before recording a reflex as absent, a re-enforcing technique (like contracting muscles in other limbs or clenching the jaws) should be tried. The hall mark of upper motor neuron deficit remains the increased deep tendon reflexes, disappearance of superficial reflexes and appearance of pathological reflexes.

The pathological reflexes include Hoffman's reflex, the Trömner reflex, the abdominal reflexes, and the plantar responses, which are useful in identifying upper motor neuron deficits. The so-called primitive or frontal lobe release reflexes (grasp, pouting, rooting, etc.) are hardly ever part of a routine clinical examination (with the possible exception of neonates) but can be carried out if the clinical situation demands it.

The cerebellum coordinates muscle contractions and movements in all voluntary muscles, and cerebellar dysfunction results in symptoms of ataxia that is truncal if the flocculonodular lobe is affected or limb ataxia if the hemispheres are at fault. Truncal ataxia is associated with disturbed gait that is typically broad based and reeling and does not get worse when eyes are closed. This can be observed when the patient walks into the examination room or when he/she is requested to walk naturally in the room. Tandem walking (10 steps), heel walking, and one leg stances (holding form more than 10 seconds) can also be tested. The Romberg's test is usually included among the tests of coordination, although it largely assesses the posterior column functions and joint position sense rather than strict cerebellar function.

The neurophysiological process of movement coordination is a complex one requiring an intact ascending sensory system, basal ganglia, the pyramidal system and the vestibular apparatus. Lesions in one of these structures may impair one or other aspect of coordination. Fortunately such lesions will usually be accompanied by other neurological manifestations that help discriminate lesions. Limb coordination to assess cerebellar function may be tested using a variety of tests: the finger-nose test, rapid finger tapping, and rapid alternating hand movements in the upper limbs, and the heel to shin test and foot tapping in the lower limbs.

Pearls of wisdom

Suggested neurological examination tests for the pain patient by the non-neurologist:

Trendelenburg-test: descending of the hip to the unaffected site with pain when walking for longer distances (insufficience of the gluteal muscles)

"Nerve stretching" tests: the Lasègue test is performed in the sitting and the supine position, and is positive if pain is felt in the back radiating to the leg with <70° of straight leg raise, especially if flexing the foot on the ipsilateral site increases the pain (Bragard test), which would be highly positive if pain starts at <35° and/or if pain is provoked with contralateral testing (malingering should be suspected if the test has different results in the sitting and supine position, or if flexion of the head does not increase the pain).

- Allocation of nerve roots:
  Hip flexion (when sitting) and patellar reflex is negative (L2)
  Knee extension (when sitting) and patellar reflex is negative (L3)
  Supination in ankle joint (when supine) and heel standing negative (L4)
  Extension of big toe (when supine) and heel standing negative (L5)
  Atrophy of gluteal muscles and standing on one leg negative (L5/S1/S2)
- Valleix pressure point test: provoking radiating pain in the leg when palpating along the pathway of the sciatic nerve on the dorsal site of the thighs
- Leg-holding test: lifting of the straight leg by 20° in the supine position for >30 seconds (if <30 seconds, suspicious for myelopathy, especially when the Babinski test is positive)
- Tuning fork test: vibration sensitivity (negative result indicates polyneuropathy)
- Babinski test: forced brushing of the sole of the foot, positive when slow extension of the big toe is observed (indicates myelopathy with pyramidal lesion)
- Brudzinski test: reflexive flexion in the hip and knee joints when bending the head
- Jackknife test: no spasticity at rest, but after passive movement of the joints, increasing spasticity followed by a sudden muscle relaxation
- Paresis grading test: the severity of paresis is graded according to Janda at six levels (0= no muscle contraction, 1 = <10%, 2 = <25%, 3 = <50%, 4 = <75%, 5 = normal strength)

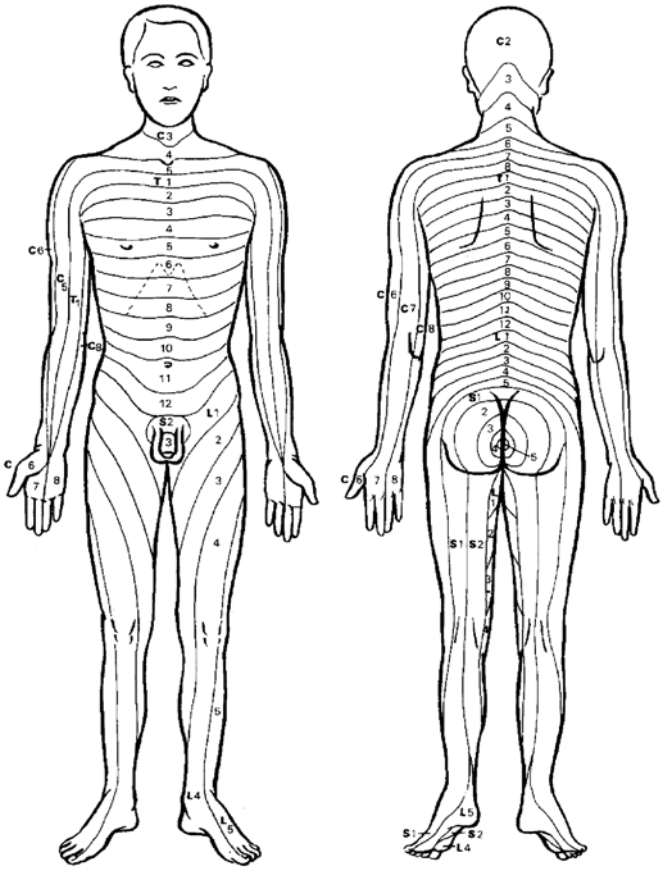

Fig. 1. A neurological body scheme, useful for differentiating and localizing radicular and nonradicular pain with the patient's subjective reports and the results from the physical examination.

- Reflex testing: biceps = C5–6, triceps = C6–7, finger II + III flexion ("Trömner") = C7–T1, patellar ligament = L2–4, and Achilles tendon = L5–S2
- Finger-nose test: a test for coordination, and the patient trying to touch his nose with his index finger in a uninterrupted ample movement with his eyes closed
- Romberg test: the patient should be able to stand stable with eyes closed, feet together, arms extended 90° to the front
- Use a simple body scheme to document the pain reported from the patient and your findings (see Fig. 1)

References

[1] Campbell WW. Pocket guide and toolkit to Dejong's neurologic examination. Lippincott, Williams and Wilkins; 2007.

[2] Cruccu G, Anand P, Attal N, Garcia-Larrea L, Haanpää M, Jørum E, Serra J, Jensen TS. EFNS guidelines on neuropathic pain assessment. Eur J Neurol 2004;3:153–62.

[3] Weisberg LA, Garcia C, Stub R. Essentials of clinical neurology: neurology history and examination. Available at: www.psychneuro.tulane.edu/neurolect.

Websites

http://www.brooksidepress.org/Products/OperationalMedicine/DATA/operationalmed/Manuals/SeaBee/clinicalsection/Neurology.pdf

http://library.med.utah.edu/neurologicexam/html/home_exam.html

http://www.neuroexam.com

http://edinfo.med.nyu.edu/courseware/neurosurgery

http://meded.ucsd.edu/clinicalmed/neuro2.htm